

Complimentary treatment for acne scars and post inflammatory pigmentation with complementary strategy using fractionated pulsed rf and Picosecond Alexandrite laser

Author: Kentaro Oku, MD. HILLS GRACE CLINIC

Dr. Oku is a paid consultant of Cynosure, LLC.

BACKGROUND:

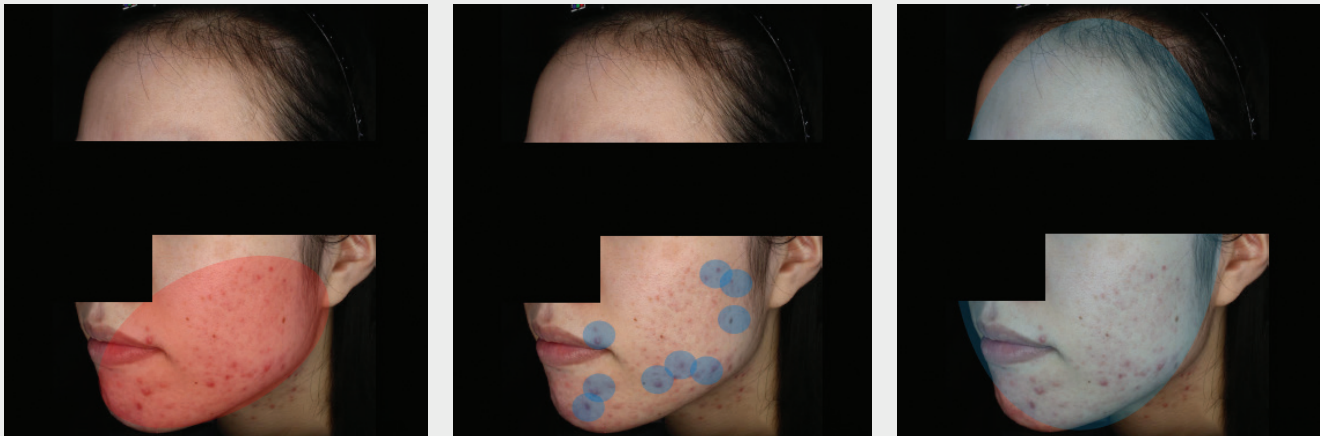Acne is a major skin issue that bothers patients in both physical and psychiatric aspects. It often leaves scars, including post inflammatory pigmentation in the epidermis and dermal degeneration. It is critical to treat patients that present with both concerns with a layered approach to get early recovery and to prevent further damage to skin tissue. This study is aimed to evaluate the safety and efficacy of complementary treatment using fractionated pulsed RF and a picosecond Alexandrite laser for a total skin revitalization treatment.

MATERIALS AND METHODS:

A set of 32 patients (30 females, 2 males, age 35.5 ± 12.1 years) who had acne scars and PIH were enrolled. All subjects were Fitzpatrick skin types II-IV. They received 3 sessions of treatment consisting of fractionated pulsed-RF irradiation with the Fusion tip immediately after applying tranexamic acid solution on the dermal damaged area followed by picosecond alexandrite laser irradiation on PIH and

inflammatory regions with 550ps, 1.31-1.70 J/cm², 1-2 stack shots on each region and 0.21-0.33 J/cm², 550ps, 1 pass for full face. The treatment interval was 6 weeks. Digital photographs and UV images with skin analysis were taken at baseline, each treatment visit, and 6 weeks post final treatment to evaluate the efficacy by an independent evaluator using the global aesthetic improvement scale (GAIS). A patient satisfaction questionnaire was completed by each patient on their last visit.

The first phase (Fractionated Pulsed RF with the Fusion tip using dense TXA on dermal damaged area), second phase (Picosecond Alexandrite Laser on PIH and individual lesions with 550 ps, 1.31-1.70 J/cm², 1-2 stack, and third phase (Picosecond Alexandrite Laser on Full face with 550 ps, 0.21-0.33 J/cm², 1 pass) are shown below:



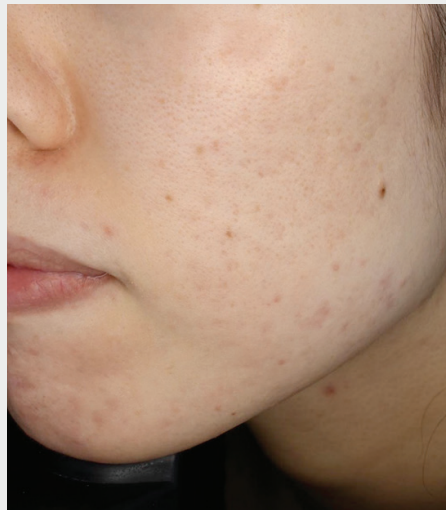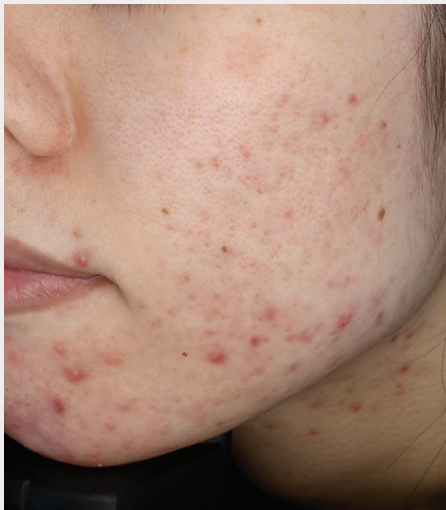RESULTS:

There was a tendency of improvement of the inflammatory region after the first treatment session, and improvement of PIH, pore size, and skin texture was seen after the second and third sessions. GAIS ratings at 6 weeks from final treatment was as follows: 7 (22%) Excess Improvement, 17 (54%) Very Improved, 7 (22%) Improved, 0 (0%) Unaltered, 0 (0%) Worsened. 78% of patients reported the satisfaction as very satisfied or satisfied on a 5-point Likert

scale. Downtime after each treatment were erythema, edematous erythema, and skin roughness, all of which resolved within 48 hours. No severe adverse reactions such as scarring or vitiligo were observed.

CONCLUSION:

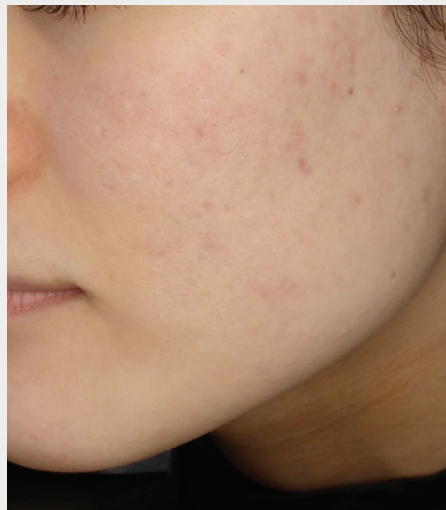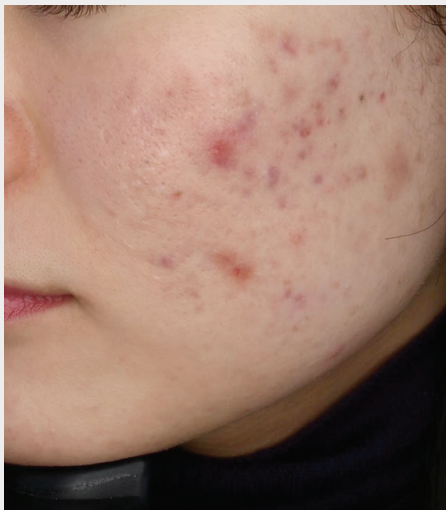The complementary treatment with fractionated pulsed RF and picosecond alexandrite laser is safe and effective to treat acne scars and PIH at the same time.



B&A 1: **29 years female**

Before and After 3 Treatments

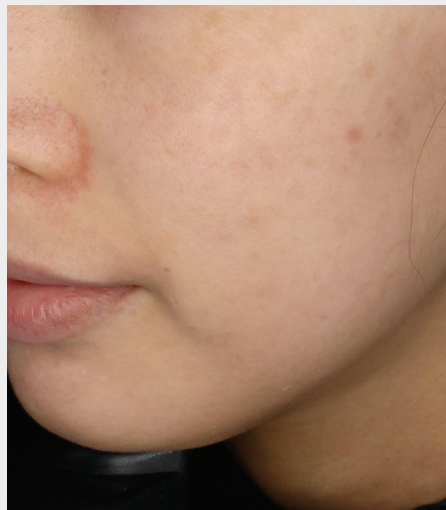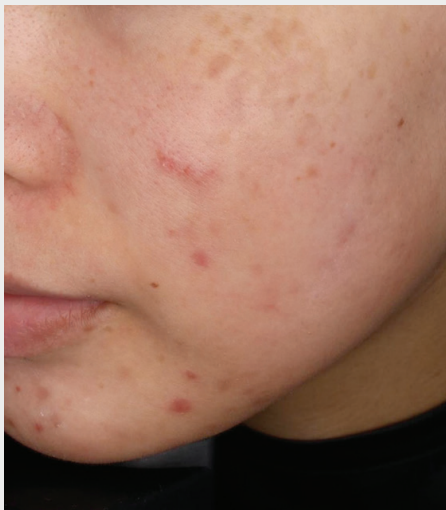Photos courtesy of Kentaro Oku, MD
HILLS GRACE CLINIC



B&A 2: **26 years female**

Before and After 3 Treatments


Photos courtesy of Kentaro Oku, MD
HILLS GRACE CLINIC



B&A 3: **23 years female**

Before and After 3 Treatments

Photos courtesy of Kentaro Oku, MD
HILLS GRACE CLINIC



CYNOSURE®
BEAUTIFUL ENERGY

© 2023 Cynosure, LLC. All rights reserved. Cynosure is a registered trademark of Cynosure, LLC. Potenza is a trademark of Jeisys Medical, Inc. The Potenza radiofrequency microneedling device is intended for electrocoagulation and hemostasis of soft tissue for dermatologic conditions. Potential side effects include temporary redness, temporary tingling, and burning sensation while receiving treatment. Like all medical procedures, not all patients are suitable for the treatment. A qualified practitioner is solely responsible for evaluating each subject's suitability to undergo treatment and for informing those being treated about any risks involved with the treatment, pre-and postoperative care, and any other relevant information. Individual results may vary and are not guaranteed. PRD-0769